

<b>REPORT DOCUMENTATION PAGE</b>		<i>Form Approved</i> <b>OMB No. 0704-0188</b>	
<small>Public reporting burden for this collection of information is estimated to average 1 hour per response, including the time for reviewing instructions, searching data sources, gathering and maintaining the data needed, and completing and reviewing the collection of information. Send comments regarding this burden estimate or any other aspect of this collection of information, including suggestions for reducing this burden to Washington Headquarters Service, Directorate for Information Operations and Reports, 1215 Jefferson Davis Highway, Suite 1204, Arlington, VA 22202-4302, and to the Office of Management and Budget, Paperwork Reduction Project (0704-0188) Washington, DC 20503.</small> <b>PLEASE DO NOT RETURN YOUR FORM TO THE ABOVE ADDRESS.</b>			
<b>1. REPORT DATE (DD-MM-YYYY)</b> 20-04-2023	<b>2. REPORT TYPE</b> Monitoring report		<b>3. DATES COVERED (From - To)</b> 2000 to 2022
<b>4. TITLE AND SUBTITLE</b> COMPREHENSIVE STRANDING INVESTIGATIONS FOR HIGH PRIORITY SPECIES		<b>5a. CONTRACT NUMBER</b>	
		<b>5b. GRANT NUMBER</b>	
		<b>5c. PROGRAM ELEMENT NUMBER</b>	
<b>6. AUTHOR(S)</b> Kristi L. West Jana Phipps Nicholas Hofmann Ilse Silva-Krott		<b>5d. PROJECT NUMBER</b>	
		<b>5e. TASK NUMBER</b>	
		<b>5f. WORK UNIT NUMBER</b>	
<b>7. PERFORMING ORGANIZATION NAME(S) AND ADDRESS(ES)</b> Hawai'i Institute of Marine Biology, University of Hawai'i at Mānoa, Kāne'ohe, Hawai'i Human Nutrition Food and Animal Sciences, College of Tropical Agriculture and Human Resources, University of Hawai'i at Mānoa, Honolulu, Hawai'i		<b>8. PERFORMING ORGANIZATION REPORT NUMBER</b>	
<b>9. SPONSORING/MONITORING AGENCY NAME(S) AND ADDRESS(ES)</b> Commander, U.S.Pacific Fleet, 250 Makalapa Dr. Pearl Harbor, HI		<b>10. SPONSOR/MONITOR'S ACRONYM(S)</b>	
		<b>11. SPONSORING/MONITORING AGENCY REPORT NUMBER</b>	
<b>12. DISTRIBUTION AVAILABILITY STATEMENT</b> Approved for public release; distribution is unlimited			
<b>13. SUPPLEMENTARY NOTES</b>			
<b>14. ABSTRACT</b> This project provides support for comprehensive stranding investigations in order to obtain increased baseline information about the health of marine mammals. Such support is essential when considering the Pacific Islands region (PIR) where unique geographical challenges exist. The PIR is comprised of isolated islands, spanning over 4 million square miles across the North, South and Western Pacific basins and includes the Hawai'i Range Complex and the Mariana Islands Range Complex. All cetacean stranding response and investigative efforts for the PIR are centralized at a dedicated stranding facility located at Marine Corps Base Hawai'i (MCBH). This specialized facility houses the University of Hawai'i (UH) Health and Stranding Lab, which plays a critical role as the only organization in the region to conduct cause of death investigations when dolphins and whales strand. This requires mounting an immediate response to each newly reported stranding event that occurs and conducting extensive necropsy examinations, including histopathology, disease surveillance, and tissue sampling in support of numerous research efforts aimed at better understanding Hawaiian cetaceans. In addition to this project facilitating advanced diagnostics in-house at the Health and Stranding Lab, we also report on progress towards characterizing marine debris ingestion by abundance and mass in stranded short-finned pilot whales.			

**15. SUBJECT TERMS**

Marine mammals, strandings, necropsy, DNA, disease, Mariane Islands Range Complex, Hawaii Range Complex

**16. SECURITY CLASSIFICATION OF:**

**a. REPORT**  
Unclassified

**b. ABSTRACT**  
Unclassified

**c. THIS PAGE**  
Unclassified

**17. LIMITATION OF ABSTRACT**  
UU

**18. NUMBER OF PAGES**  
10

**19a. NAME OF RESPONSIBLE PERSON**  
Department of the Navy

**19b. TELEPHONE NUMBER (Include area code)**  
808-471-6391

## **Comprehensive Stranding Investigations for High Priority Species**

West, K.L.<sup>1,2</sup>, Phipps, J.<sup>1,2</sup>, Hofmann, N.<sup>1</sup>, and I. Silva-Krott<sup>1</sup>

<sup>1</sup>Hawai'i Institute of Marine Biology, University of Hawai'i at Mānoa, Kāne'ohe, Hawai'i

<sup>2</sup>Human Nutrition Food and Animal Sciences, College of Tropical Agriculture and Human Resources, University of Hawai'i at Mānoa, Honolulu, Hawai'i

### ***ABSTRACT***

This project provides support for comprehensive stranding investigations in order to obtain increased baseline information about the health of marine mammals. Such support is essential when considering the Pacific Islands region (PIR) where unique geographical challenges exist. The PIR is comprised of isolated islands, spanning over 4 million square miles across the North, South and Western Pacific basins and includes the Hawai'i Range Complex and the Mariana Islands Range Complex. All cetacean stranding response and investigative efforts for the PIR are centralized at a dedicated stranding facility located at Marine Corps Base Hawai'i (MCBH). This specialized facility houses the University of Hawai'i (UH) Health and Stranding Lab, which plays a critical role as the only organization in the region to conduct cause of death investigations when dolphins and whales strand. This requires mounting an immediate response to each newly reported stranding event that occurs and conducting extensive necropsy examinations, including histopathology, disease surveillance, and tissue sampling in support of numerous research efforts aimed at better understanding Hawaiian cetaceans. In addition to this project facilitating advanced diagnostics in-house at the Health and Stranding Lab, we also report on progress towards characterizing marine debris ingestion by abundance and mass in stranded short-finned pilot whales.

### ***SUMMARY OF STRANDING CASES DURING CALENDAR YEAR 2022***

Stranding response, necropsy and cause of death investigative summaries were provided for 18 stranding events that occurred during calendar year 2022. However, in several other cases, additional cetacean strandings in the main Hawaiian Islands were confirmed and responses mounted but are not reported here because of limitations that precluded necropsy and/or sample collection. These include a humpback whale that stranded dead on Ni'ihau where a necropsy team was on the island of Kaua'i enroute to Ni'ihau when movement of the carcass and subsequent shark predation made proceeding with a necropsy unsafe. Other examples include a confirmed dead bottlenose dolphin underwater at a popular dive site in Kailua Kona that was no longer present upon a retrieval effort and a dead striped dolphin at the bottom of a shallow boat channel in Kailua Kona that was gone the following morning when retrieval of the carcass was attempted. Verified or unverified stranding reports may not result in the death of an animal and/or the collection of a biological sample. In these types of stranding response scenarios, a case number is not assigned, and the event is not documented with a unique specimen identification number that is tracked in the Health and Stranding Lab records. Therefore, while we have reported on a total of 18 stranding cases during the calendar year 2022, additional responses were mounted in association with reports of strandings of both confirmed dead stranded animals, unverified reports of dead stranded cetaceans and strandings of live animals, such as a confirmed live beaked whale stranding off of

Hawaii Island in 2022. Photographs and video footage were obtained of a Cuvier's beaked whale that had stranded on March 25<sup>th</sup>, 2022 with public reporting of the event occurring the following morning. The animal had swam into Honaunau Bay and had to avoid swimmers and snorkelers before hitting shoreline rocks. This Cuvier's beaked whale was guided back to sea by residents after hitting the rocks with bleeding observed below the pectoral fin and on the tail. This event occurred between 3:30 and 4:00 pm and this stranding was coincident in time with public reports of active sonar occurring during the stranding and observation of a navy destroyer offshore.

The summary cases reported on in 2022 that include cetacean strandings where full necropsies or sampling was conducted are indicated by a unique specimen identification number used for the n2022 calendar year, the UH Health and Stranding lab coordinated or conducted stranding responses, necropsy and sample collections over a wide geographical range that includes five of the main Hawaiian Islands (Hawai'i, O'ahu, Maui, Moloka'i and Kaua'i) as well as the Commonwealth of the Northern Mariana Islands (Tinian), the Marshall Islands (Kwajalein Atoll), and American Samoa. These responses resulted in sample collections and specimen tracking at the UH Health and Stranding Lab from a confirmed total of ten different cetacean species including sperm whale, *Physeter macrocephalus* (3), humpback whale, *Megaptera novaeangliae* (3), striped dolphin, *Stenella attenuata* (1), spinner dolphin, *Stenella longirostris* (2), melon-headed whale, *Feresa attenuata* (1), Fraser's dolphin, *Lagenodelphis hoseii* (1), pilot whale, *Globicephala macrorhynchus* (1), Cuvier's beaked whale, *Ziphius cavirostris* (1), bottlenose dolphin, *Tursiops truncatus*, (1), pygmy sperm whale, *Kogia breviceps* (2) and an unidentified beaked whale. An assumed humpback whale placenta sample was also collected but was determined to represent a marlin, *Makaira nigricans*, upon in-house genetic analysis. Specimens represented various reproductive stages including newborn calves, juveniles, sexually mature males and females and pregnant females.

Case highlights from quarterly reports submitted during the reporting period are included below. These include the first discovery of lobomycosis like disease in the central Pacific in a Fraser's dolphin, a humpback whale neonate that is believed to have died from a concussive force to the head and a bottlenose dolphin necropsy, the stranding of which resulted from a fishery interaction with an esophageal perforation of a fishing hook with line trailing from the animal's mouth.

### ***Fraser's Dolphin, Lagenodelphis hoseii, Kaipukaihina beach, Maui***

A live Fraser's dolphin was reported stranded on the island of Maui on 04/24/2022 around 9 am. Nicole Davis (NOAA PIRO) and her on-site volunteer team on Maui responded to the initial report of the live stranded animal, where it was examined by local veterinarians and euthanized. The carcass was wrapped in preparation for air cargo transport and put on ice prior to the cargo flight to O'ahu, where it arrived at around 2:30 am the following morning. Nicholas Hofmann from the Health and Stranding Lab coordinated its transportation to the lab, where it was kept on ice until the necropsy was performed that day, starting at 8:00 am.

Prior to the start of necropsy conducted water displacement of the carcass was conducted to provide an empirical measurement of the total body volume of the animal. The Health and Stranding Lab also facilitated a collaborative effort to obtain a 3D body scan of the carcass with the Marine Mammal Research Program (MMRP) at the Hawaii Institute of Marine Biology that

utilized scanning technology to generate a permanent record of morphometrics and form as well as an estimate of total body volume for comparison to our empirical measurement. A standard suite of morphometrics and comprehensive external examination of the animal was also conducted as part of the necropsy. Further efforts to assess body condition metrics in Fraser's dolphin involved blubber thickness and histological examination from blubber samples collected at major anatomical landmarks across the body topography. This included blubber sampling at 5 points across 7 anatomically identified girth axes providing a total of 35 sampling locations where blubber will provide valuable data regarding blubber morphological variation by girth and body plane and its relation to overall body condition in Fraser's dolphins. The individual's total body length was 247 cm and the weight was 169.9 kgs. The animal was an adult male. The external examination noted numerous healed rake marks and cookie cutter bites around both sides of its body, as well as two unhealed cookie cutter bites. One of the unhealed bites was located above its left pectoral fin, measuring 2 x 1 cm. The second was located on the right side behind the dorsal fin, measuring 5 x 2.5 cm. The animal had an abrasion at the tip of its mandible which was likely due to the stranding event, and a few other superficial cuts that may have occurred post-mortem. There was an abnormal lesion, marked "Lesion A", on the animal's right side, dorsal and cranial to the anal slit, where skin appeared blistered. It was noted that this could possibly have been a sign of disease and a dedicated sample was collected for formalin fixed processing and ultracold frozen storage in effort to facilitate disease screening of this specific lesion.

Many missing teeth were noted on both the top and bottom jaws during the external examination. During the internal examination, the right prescapular lymph node had multiple pale, firm structures, measuring around 1 mm in diameter and 1 cm in length. The left marginal lymph node was slightly enlarged, and red and mottled in coloration. Both lungs had edema present, but the right lung had an unusual raised, dark red region that was 2 cm in diameter with a measured depth of 5 cm into the lung tissue. It was noted that this may have been a hemorrhage and a specific sample of the area was collected and fixed in formalin to evaluate signs of hemorrhage later histologically. The liver was congested and had an observable groove in the liver tissue from the impact of a 50 cm long, 3.5-4 cm diameter clot that was present in the vena cava. The heart had extensive clotting within it, including a "chicken fat clot" on the left side which obstructed the valve between the left atria and ventricle. While the right side had initially been noted as being "puffy", this seemed to have dissipated as the heart was examined and may have represented blood. The pancreas was noted as abnormal once removed from the body cavity and examined. There were almost no stomach contents or feces present in the gastrointestinal tract and eight small ulcers were noted in the forestomach, all measuring <0.5 cm in size. Around 30 ml of urine was present in the bladder, and it was discolored, turgid, and viscous. Urinalysis was conducted during necropsy on a sample of urine and a sample was collected and frozen. The testes size was consistent with a mature male and testes were grossly normal. Between the cerebrum and cerebellum, a subdural blood clot was noted as well as congestion in the area. The pituitary gland was located and sampled for further testing.

Due to the recent discovery of a novel morbillivirus in a Fraser's dolphin that stranded in Maui in 2018, morbillivirus screening of tissues from the stranded Fraser's dolphin was conducted at the Health and Stranding Lab. All tissues tested were negative for morbillivirus. This individual was also tested in-house for herpes virus because of the prominent "Lesion A" observed and sampled during the external examination. All tissues tested were also negative for herpes virus. A

significant finding upon histopathology involved examination of the tissue comprising “Lesion A”. We observed histopathological findings in this location that are consistent with Lobomycosis, a fungal disease that has not previously been described from the central Pacific. Lobomycosis impacts both dolphins and humans, with prior reports of this fungal disease in dolphins primarily from tropical and sub-tropical waters off Central and South America and off the east coast of the United States. Recent genetic work raises questions about the classification and nomenclature of the fungus, resulting in these skin lesions being referred to as lobomycosis like disease. Lobomycosis like disease is only described from humans and dolphins, with the initial report arising from a human patient in Brazil prior to identification of the fungal disease in dolphins off the Brazilian coast. Reports of lobomycosis like disease in dolphins are focused on Brazil, Venezuela, Mexico, Florida, South and North and South Carolina. There are no prior reports to our knowledge of lobomycosis like disease in a Hawaiian cetacean or from any other host in the central Pacific. Current efforts to further investigate this case involve the application of molecular methods in-house to identify and confirm the specific fungus causative of the pathology associated with the significant skin lesion.

### ***Humpback whale calf, *Megaptera novaeangliae*, Wailupe, O‘ahu***

A recently deceased male humpback calf was reported at Wailupe Beach Park on 02/06/2022 early in the morning. The initial report from the general public stated that the animal was alive, however, first responders did not observe any obvious signs of life. Health and Stranding Lab staff arrived at the beach at 9:20 am and were joined by NOAA and Hawaii Marine Animal Response (HMAR) personnel in mounting a joint response to this event. Upon arrival of NOAA’s contract veterinarian, Dr. Gregg Levine, the animal’s status was evaluated, and the animal was confirmed dead. Working with HMAR, Health and Stranding Lab staff and volunteers transported the calf from the water to the lab’s stranding truck using stretchers, straps, a trailer, and a large amount of labor to make the subsequent lifts. No heavy equipment was deployed. As a part of the removal process cultural practitioners conducted a blessing of the carcass before it was taken off the beach. During the movement process the whale sustained multiple post-mortem lacerations due to the rocky nature of the beach. The animal was then transported to the lab for necropsy which began immediately upon arrival at the lab, at approximately 4:30 pm.

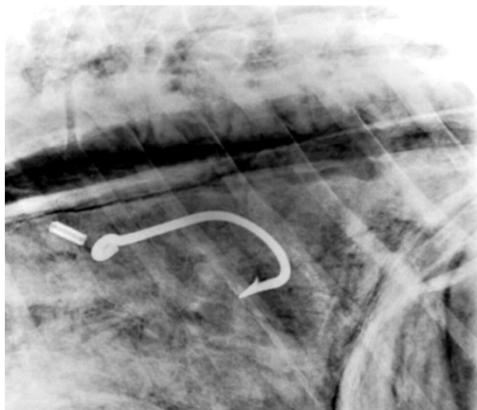
In addition to the external examination and a suite of morphometrics that are standard practice at the Health and Stranding Lab facility, the carcass was scanned with a 3D body scanner as a part of a collaborative project with MMRP. Along with the data obtained from scanning, the body condition of this animal will be further examined through histological evaluation of the blubber using slides made from blubber samples collected at key locations across the body topography. This includes blubber sampling at 5 points across 7 anatomically identified girth axes. This total of 35 sampled locations will provide data regarding blubber morphological variation and its relation to overall body condition in humpback whale calves. During the external examination the calf’s umbilicus was assessed as partially healed, and whiskers were present on the rostrum. From these findings it was found to be likely that the calf was less than a week old. We believe this was a relatively small calf, as humpback calves are typically born between 4 and 4.5 m and this animal was measured at 3.75 m in length. We broadly estimated that the carcass weighed between 450 and 550 kg. as it was not possible to weigh the carcass and regression equations describing the relationship between humpback whale calf weight and length are not available.

Our findings upon internal examination suggested that the animal may have been slightly jaundiced. While the stomach was empty, it was found that the calf had nursed before death as abundant urine was found in the bladder. The collected urine was dark, and a urinalysis test showed it contained a high amount of blood. The lungs contained air however they were abnormal in texture with mottled coloring as well as signs of pulmonary edema. The heart had pulmonary ductus arteriosus, a large sinus connecting the pulmonary artery and aorta yet to close, but this condition is consistent with other humpback calf hearts that have been examined and likely was not a contributor to the cause of death. The right and left sides of the heart were both 4 cm thick, which is to be expected from a calf of this age. The left kidney had a yellow gelatinous irregularity on the caudal end of the external surface, about 8 x 10 cm in surface area. Abnormalities, such as enlarged sizes and white dots, were reported in both the mediastinal and right marginal lymph nodes. Large amounts of hemorrhaging in the brain, including contralateral hemorrhage, suggested an impact of blunt force trauma may have been the cause of death in this case. This concussive force may have resulted from another whale but, more likely, was caused by a vessel strike. Extensive samples from all body systems and organs as well as baleen was collected and are stored at the Health and Stranding Lab. Baleen analysis for hormone and stable isotopes as well as infectious disease screening for several pathogens known to impact the health of Hawaiian cetaceans are currently pending for this case. Histopathology results are also pending.

***Bottlenose dolphin, *Tursiops truncatus*, Hilo, Hawai'i***

On May 9<sup>th</sup>, 2020 a large adult male bottlenose dolphin was reported dead and floating off of the break wall in Hilo Bay. Due to the limited personnel available to respond in any capacity because of COVID-19 and the large size of the animal, it was not able to be removed immediately. The animal was determined to be in an advanced state of decomposition, and it was tarped and secured behind locked gates overnight. The next morning the carcass was wrapped by NOAA and Health and Stranding Lab affiliated stranding responders with the aid of heavy equipment provided by the Department of Public Works that also assisted with transporting the carcass to Transair for shipment to O'ahu. After being placed in the Transair chiller in Hilo, the carcass was flow to O'ahu on May 11<sup>th</sup>, 2020. It was picked up in the morning by Nicholas Hofmann and transported to the Health and Stranding Lab facility where it was transferred to the walk-in freezer for future examination. The decision was made to freeze the carcass and postpone the necropsy due to the animal's advanced state of decomposition and the restrictions on necropsy staffing due to COVID-19.

The adult male bottlenose dolphin was measured to be 293 cm in length and weighed approximately 273 kg (estimate from Whale Scale app). It had a fishing hook in the mouth with about 326 cm fishing line hanging out of the mouth cavity that were photographed in Hilo immediately upon its retrieval from the ocean, but the fishing gear was not manipulated during preparation for transport and shipping. This individual's dorsal fin profile was matched to the Cascadia Research Collective catalog and this individual has been documented one time



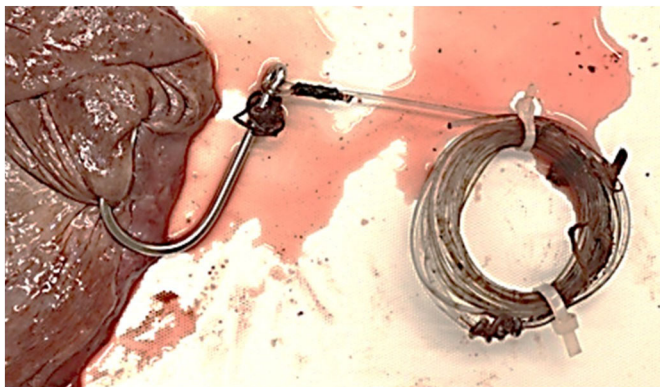
previously, in 2012 off Kawaihae on Hawai'i island. The sighting of this individual was part of a very large bottlenose dolphin group encounter where most individuals have only been seen once, indicating that the group may have spent most of its time outside of the Cascadia Research Collective study area. A necropsy was scheduled of the frozen carcass on October 17th, 2022 at MCBH. The necropsy included both an external and internal examination led by Dr. Kristi West and radiographic imaging was conducted by Dr. Gregg Levine as a collaborative effort between the Health and Stranding Lab and Dolphin Quest who provided the portable x ray machine. Radiographic imaging confirmed location of lead leader and fishing hook in the esophagus of the animal

prior to the internal necropsy examination.

The external examination indicated multiple cookie cutter wounds in different states of healing along the body. Two bites were located on the left lateral side between the genital slit and anus, measuring 4.5 cm x 3.7 cm (dorsal), and 5.6 cm x 3.8 cm (ventral). Another, measuring 4.5 cm x 3.7 cm, was located between the umbilicus and genital slit. A relatively recent wound measuring 4.6 cm x 2.8 cm was located equidistant between the blowhole and dorsal fin. The last notable cookie cutter bite was on the left side of the caudal peduncle, but there were signs of many healed cookie cutter wounds along the body. The fishing line in the mouth of the animal was measured to be 326 cm long and was clearly cut. Many teeth were missing, and all were fairly worn down until they were blunt, which suggests that this likely represents an older individual.

The internal examination indicated several abnormalities. The 4th rib on the left was broken along the inside of the body cavity, however it's unclear whether this was a pre or postmortem fracture.

The heart had small bacterial colonies on the left ventricle and clotting inside the of right ventricle. The esophagus was very enlarged around the hook's location of perforation. The hook was embedded in the esophagus with a full perforation through the tissue. It would have been impossible for the hook to be removed through vomiting. The stomach was full of stomach lining due to degradation, but otoliths and lenses of fish were also present.





No feces were observed in the colon and there was no urine in the bladder. Similar to the heart, the liver had many bacterial colonies observed on the external surface. The cerebrum and cerebellum were able to be differentiated but were both very decomposed. Internal examination of the reproductive system confirmed that this animal was an adult male. Although cause of death in this case is believed to be a direct result of the ingestion and perforation caused by the fishhook, histopathology, limited due to decomposition and freezing, as well as disease screening is currently pending.

**MARINE DEBRIS OPTION**

The UH Health and Stranding Lab has removed significant masses of marine debris from three necropsied pilot whales. Progress has been made over the past year in the cleaning and detangling of the marine debris from all three animals. Sorting, counting, and categorizing by type and size class has been completed for two of the three animals as well as weights of each size and type determined (Figures 1 & 2). Funding for this objective ended in FY22 and submitted quarterly reports have focused on the comparison of findings between the two pilot whales where marine debris counts and size measurements by type were completed. In this annual report, we also present the incomplete marine debris count data that was obtained from the third individual pilot whale for preliminary comparisons with the two individuals where counts are complete.

Comparisons between debris item counts and weights from the two completed pilot whales, one which stranded on O‘ahu in 2014 and one which stranded on Kaua‘i in 2017, demonstrated that in both individuals, monofilament line dominated across the categories examined with monofilament line comprising 55.1% in the 2014 O‘ahu animal and 62.13% in the 2017 Kaua‘i animal. In the 2017 Kaua‘i animal, the next most dominant category of marine debris was sheet plastic (20.74%) in contrast to the 2014 O‘ahu animal where the next most dominant category was multifilament line (29%). The third most dominant categories of marine debris were alternatively multifilament line and sheet plastic in the 2014 and 2017 stranded pilot whales (Figure 2).

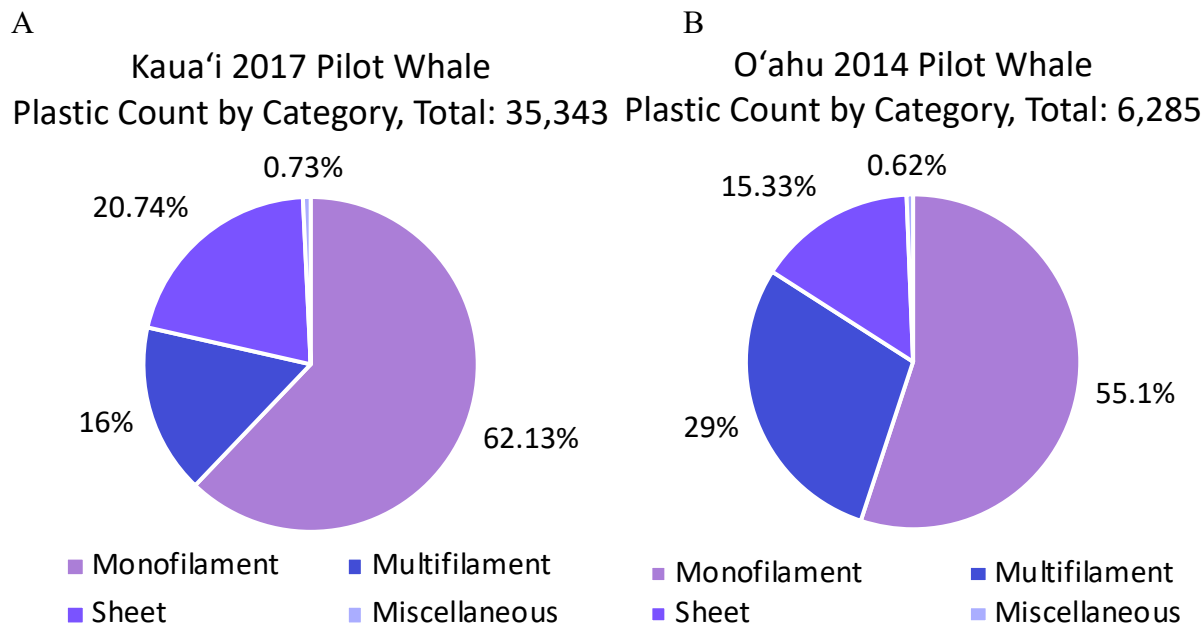


Figure 1: Comparison of marine debris examination of two pilot whales, one which stranded on Kaua'i in 2017 (A), and one which stranded on O'ahu in 2014 (B). Figure shows total plastic by type category quantified by count. Miscellaneous category includes categories of hard fragment and foam in addition to miscellaneous plastic items.

Weight values for these type and size categories have been measured for these two animals and the relative contribution of groups does not mirror that of the count information (Figure 2). The category shown to be the greatest contributor by weight in both animals was multifilament, with 72% and 80% of the plastic belonging to this category in the 2014 O'ahu animal, and 2017 Kaua'i animal, respectively. The next greatest contributor in 2014 O'ahu animal was miscellaneous plastics accounting for 22% of the total plastic weight and in the 2017 Kaua'i animal 12.8% of the plastic weight was attributed to sheet plastic (Figure 2). Furthermore, it is important to note that while the miscellaneous category accounted for less than 1% of the plastic count in the Oahu 2014 animal, this category accounted for 22.7% of total weight. This weight disparity was due to one object, a large eel trap (Figure 3), accounting for one of the pieces that fell in the miscellaneous category. The discrepancies between greatest contributors between the count and weight measurements, as well as the relative impact a single large plastic object can have, illustrates the importance of distinguishing between methods when assessing the potential impact of some marine debris categories over others in the case of cetacean ingestion (Figures 1, 2 & 3).

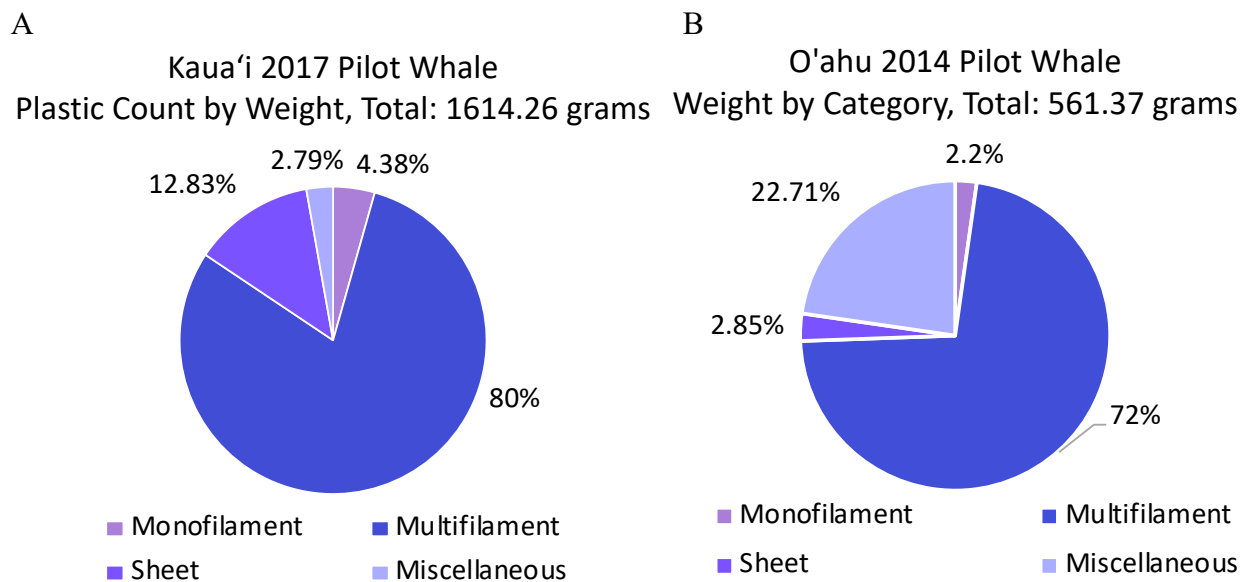


Figure 2: Comparison of marine debris examination of two pilot whales, one which stranded on Kaua'i in 2017 (A), and one which stranded on O'ahu in 2014 (B). Figure shows total plastic by type category quantified by count. Miscellaneous category includes categories of hard fragment and foam in addition to miscellaneous plastic items.



Figure 3: Image of the large eel trap found in the stomach of the 2014 O‘ahu pilot whale.

In addition to the complete data collected in terms of counts and weight of ingested marine debris from the 2014 Kaua‘i and the 2017 O‘ahu pilot whales, sorting, counting, and categorizing by marine debris type and size class has been started for the third animal which stranded in 2013 off Lāna‘i. To date, 12,924 individual pieces of marine debris has been assessed for size category and marine debris type category (Figure 4). This animal to date demonstrates that monofilament line dominates across the marine debris type categories (61.64%) followed by sheet plastic (27.73%) as was seen in the 2017 Kaua‘i animal (Figure 1 & 4).

Lāna‘i 2013 Pilot Whale  
Plastic Count by Category, subtotal: 12,924

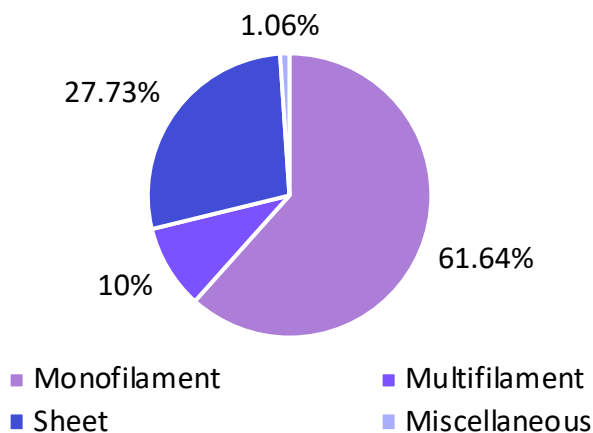


Figure 3: Plastic counts by category for a pilot whale which stranded on Lāna‘i in 2013. This figure shows preliminary data of incomplete categorization and counts of plastics from this animal. Miscellaneous category includes categories of hard fragment and foam in addition to miscellaneous plastic items.

Marine debris ingestion presents a significant threat to cetaceans world-wide. This was highlighted in the Pacific Islands by the recent 2023 stranding of a sperm whale on Kaua‘i where marine debris ingestion was believed to have resulted in an intestinal blockage that caused the death of this whale. The pilot whale marine debris work to date is the first effort to document the type and size range of marine debris that threatens cetaceans in the central Pacific, and we have categorized and

measured individual marine debris items that total over 6,000 items in one animal over 35,000 in another individual. Completion of this project involves continuation of categorization and size measurements of a third pilot whale where over 12,000 individual marine debris items have been categorized to date. Additionally, we hope to conduct polymer analyses of a total of 100 marine debris items ingested across the three individual pilot whales to better understand the origination of the marine debris ingested and aid in mitigation efforts. The proposed completion of this project is anticipated to provide valuable insight into the relative impact of different types of marine debris on cetaceans in the central Pacific.

### **ACKNOWLEDGEMENTS**

Funding for this project was provided by Commander, United States Pacific Fleet, Environmental Readiness Division. We would also like to acknowledge the Prescott Grant program for support of stranding response, necropsy and the collection of archived and current samples that allow for advanced diagnostics. This work was conducted under NOAA National Marine Fisheries Service Permit #18786. Special thanks goes to Cody Clifton and the volunteers at the Health and Stranding lab for sample collection and preservation, as well as to the numerous stranding volunteers throughout the Hawaiian Islands and Pacific island territories that assisted in the collection of samples during remote stranding events and necropsy.

Suggested citation:

West, K.L., Phipps, J., Hofmann, N., Silva-Krott, I. (2022). *Comprehensive stranding investigations for high priority species* (Marine Species Monitoring Program Annual Report). United States Navy.